Idiopathic inflammatory myopathies related lung disease in adults

Sameep Sehgal, Aditi Patel*, Soumya Chatterjee, Anthony P Fernandez, Carol Farver, Ruchi Yadav, Yuebing Li, Sonye K Danoff, Didem Saygin, Julio A Huapaya, Erin M Wilfong, Kristin B Highland*

Lancet Respir Med
2025; 13: 272–88

Published Online
November 29, 2024
https://doi.org/10.1016/S2213-2600(24)00267-4

*Contributed equally

Department of Pulmonary and Critical Care Medicine, Integrated Hospital Care Institute (S Sehgal MD, K B Highland MD), **Department of Rheumatologic and Immunologic Disease** (A Patel MD, S Chatterjee MD), **Department of Dermatology, Medical Specialty Institute** (A P Fernandez MD PhD), **Department of Pathology** (A P Fernandez, C Farver MD), **Department of Diagnostic Radiology, Diagnostic Institute** (R Yadav MD), **and Department of Neurology, Neurological Institute** (Prof Y Li MD), **Cleveland Clinic, Cleveland, OH, USA; Division of Pulmonary and Critical Care Medicine, Johns Hopkins University, Baltimore, MD, USA** (Prof S K Danoff MD); **Division of Rheumatology and Clinical Immunology, University of Pittsburgh, Pittsburgh, PA, USA** (D Saygin MD); **Critical Care Medicine and Pulmonary Branch, National Heart, Lung, and Blood, Institute, National Institutes of Health, Bethesda, MD, USA** (J A Huapaya MD); **Division of Rheumatology and Immunology, Division of Pulmonary and Critical Care Medicine, Vanderbilt University Medical Center, Nashville, TN, USA** (E M Wilfong MD)

Correspondence to Sameep Sehgal, Department of Pulmonary and Critical Care Medicine, Integrated Hospital Care Institute, Cleveland Clinic, Cleveland, OH 44195, USA
sehgals@ccf.org

Interstitial lung disease (ILD) is common in idiopathic inflammatory myopathies in adults, especially in patients with antisynthetase syndrome and anti-MDA5 antibody-associated dermatomyositis. Pulmonary manifestations can range from subclinical ILD to rapidly progressive respiratory failure. Coexistent myositis, characteristic skin lesions, arthritis, and Raynaud's phenomenon are common. However, 16–65% of patients present with isolated lung disease. Detection of myositis-specific and myositis-associated antibodies can aid in diagnosis and disease characterisation. Chest imaging and pathology most commonly show non-specific interstitial pneumonia and organising pneumonia patterns. Immunosuppression is the mainstay of management with aggressive combination treatment for rapidly progressive disease and incremental escalation as needed for chronic ILD. The addition of antifibrotic agents is an option in progressive fibrotic disease, and lung transplantation can be considered in severe, end-stage disease. Most patients respond to treatment, but short-term mortality remains high for patients with rapidly progressive disease associated with anti-MDA5 antibody ILD.

Introduction

Idiopathic inflammatory myopathies are a heterogeneous group of diseases primarily characterised by the common feature of immune-mediated inflammation of muscle fibres and surrounding tissues. The annual incidence of idiopathic inflammatory myopathies ranges from 0·2–2·0 per 100 000 person-years, with a prevalence ranging from 2–25 per 100 000 people.[1] However, these systemic diseases can manifest with a combination of inflammatory muscle, skin, lung, and joint disease. With clinical features, serology, and muscle pathology, currently six main phenotypes have been described in adults. Each phenotype has a distinct typical presentation (table 1).[2]

First, antisynthetase syndrome is the presence of anti-aminoacyl-tRNA synthetase antibodies with interstitial lung disease (ILD), inflammatory myopathy, arthritis, or mechanic's hands. Dermatomyositis manifests as typical skin findings with muscle weakness. A subgroup of patients have skin findings with no clinical muscle disease and are characterised as having clinically amyopathic dermatomyositis. Overlap myositis is inflammatory myopathy with simultaneous presence of features of other autoimmune diseases, such as systemic sclerosis, mixed connective tissue disease, or Sjögren's syndrome. Immune-mediated necrotising myopathy describes myopathy with muscle biopsy features of myonecrosis without a considerable number of inflammatory cells. Inclusion body myositis is asymmetric myopathy at disease onset presenting with quadricep weakness and finger flexor weakness at diagnosis or later in the disease course. Muscle biopsy shows endomysial inflammatory infiltrate and muscle fibres with rimmed vacuoles and eosinophilic muscle fibre inclusions. Patients with inclusion body myositis usually do not respond to immunosuppression treatment. Lastly, polymyositis is a rare subtype defined as myositis with the absence of features that would classify patients in the other subgroups.

Idiopathic inflammatory myopathies can affect multiple compartments of the respiratory system including lung parenchyma (resulting in ILD), pulmonary vasculature (leading to pulmonary hypertension), and respiratory muscles. Aspiration pneumonitis or pneumonia from dysphagia is also seen. ILD is the most common pulmonary manifestation, with an overall estimated prevalence of 40–50%. However, in patients with anti-melanoma differentiation-associated

Key messages

- Interstitial lung disease (ILD) is common in patients with idiopathic inflammatory myopathies, especially those with antisynthetase syndrome and anti-MDA5 antibody.
- The clinical presentation of idiopathic inflammatory myopathy-associated ILD can vary from mild asymptomatic disease to acute respiratory failure. Nonspecific interstitial pneumonia and organising pneumonia are the most common patterns observed on imaging and pathology.
- Extrapulmonary manifestations of myositis, skin rash, arthritis, and Raynaud's phenomenon are common. Lung disease might present in isolation or precede extrapulmonary disease. The presence of myositis-specific and myositis-associated antibodies can help to establish the diagnosis and characterise the clinical disease.
- Immunosuppression is the mainstay of treatment for pulmonary and extrapulmonary manifestations of idiopathic inflammatory myopathies. Early, high-potency combination treatment is used with a step-down approach in rapidly progressive disease. Conversely, slow, incremental escalation of immunosuppression is preferred for chronic ILD in a step-up approach.
- Most patients improve or stabilise on treatment; however, mortality remains high for rapidly progressive disease. Lung transplantation is an option for severe, progressive disease in a subgroup of patients.

	Lung	Muscle	Skin	Characteristic features
Dermatomyositis (classic dermatomyositis rash with or without myositis)				
Anti-MDA5	Rapidly progressive ILD	Mild to amyopathic	Cutaneous ulcerations	High mortality; mediastinal emphysema
Anti-SAE	No known association	Typically absent initially and developed later	Classic dermatomyositis rash	Severe skin rashes
Anti-Mi2	Infrequent	Markedly elevated creatine kinase level	Classic dermatomyositis rash	Good response to therapy
Anti-NXP-2	No known association	Severe muscle disease at onset	Dermatomyositis rash; calcinosis; oedema	High malignancy risk
Anti-TIF1γ	Infrequent	Mild to amyopathic	Severe dermatomyositis rash; calcinosis	High malignancy risk
ASyS (antisynthetase antibody plus combination of lung, muscle, or skin involvement)				
Anti-Jo-1 (most common antisynthetase syndrome antibody)	Frequent (80–86%)	Frequent (90%)	Dermatomyositis-associated skin rashes; mechanic's hands; Raynaud's phenomenon	Arthralgia; fever; puffy hands
Anti-PL-12	Frequent (88–90%)	Myositis or myalgia (52%)	Mechanic's hands	Arthralgia
Anti-PL-7	Always present	Frequent	Mechanic's hands; Raynaud's phenomenon	Can have rapidly progressive ILD
Anti-OJ	Frequent	Infrequent	Infrequent	Isolated ILD
Anti-EJ	Frequent	Frequent	Gottron's sign	Better outcomes of the antisynthetase antibody
Anti-KS	Frequent	Rare	Mechanic's hands; Raynaud's phenomenon	Isolated ILD
Overlap myositis (myositis with concomitant features of other connective tissue disease)				
Anti-PM/SCL antibody	At onset of disease (10%), eventually 60% developed ILD	Frequent	Sclerodactyly; Raynaud's phenomenon; dermatomyositis rashes; calcinosis	Muscle disease associated with severe disease phenotype
Anti-Ku	Prevalence of ILD (35%)	Mild muscle disease	Limited systemic sclerosis features; Raynaud's phenomenon	Can have severe steroid-resistant ILD
Anti-U1-RNP	Prevalence of ILD (50%)	Myopathy can be seen	Raynaud's phenomenon; digital ulceration; puffy fingers	Mixed connective tissue disease; pericarditis and glomerulonephritis
Anti-U3/RNP	Prevalence of ILD (38%)	Myopathy can be seen	Diffuse systemic sclerosis features	Pulmonary hypertension; high mortality
Anti-Ro52	Higher ILD rates if seen with antisynthetase syndrome	Frequent	Dermatomyositis rashes; cutaneous lupus	Most common myositis-associated antibody; can be seen with antisynthetase syndrome
Anti-SRP	ILD more prevalent	Severe myopathy	Not commonly reported	Cardiac involvement; dysphagia; can have refractory disease
Anti-HMGCR	No known association	Severe myopathy	No association	Associated with statin use
Inclusion body myositis				
Anti-cN1A	No known association	Asymmetric myopathy with distal weakness	Has been reported with systemic sclerosis and systemic lupus erythematosus	Poor response to immunosuppression

ILD=interstitial lung disease.

Table 1: **Clinical phenotypes of immune-mediated myositis and associations with antibodies**

protein 5 (MDA5)-dermatomyositis and antisynthetase syndrome, the prevalence is more than 80%.[3] The prevalence of anti-MDA5-dermatomyositis is higher in Asian cohorts than European cohorts.[4,5] ILD in idiopathic inflammatory myopathies can be progressive and carries high morbidity and mortality. Treatment refractory and rapidly progressive disease has been associated most with anti-MDA5-dermatomyositis.[6,7]

This Review will discuss pulmonary and extrapulmonary clinical manifestations, diagnostic evaluation, treatment options, management approach, and future directions in adult patients with idiopathic inflammatory myopathy-associated ILD (IIM-ILD). We focus on antisynthetase syndrome and dermatomyositis; however, the principles can apply to any idiopathic inflammatory myopathy lung disease phenotype.

Pathobiology

The underlying mechanism of antisynthetase syndrome and dermatomyositis is postulated to be chronic inflammation caused by both innate and adaptive immune activation triggered by interactions between genetic and environmental risk factors (figure 1). Several HLA and non-HLA genetic associations have been shown in idiopathic inflammatory myopathies.[8] Epidemiological studies have reported smoking as a risk factor for antisynthetase syndrome.[9] Preceding respiratory and gastrointestinal infections are associated with idiopathic inflammatory myopathy onset, specifically Coxsackievirus for dermatomyositis and anti-MDA5 dermatomyositis.[8,10] Recently, SARS-CoV-2 infection has been associated with idiopathic inflammatory myopathy onset.[11] Medications such as statins,

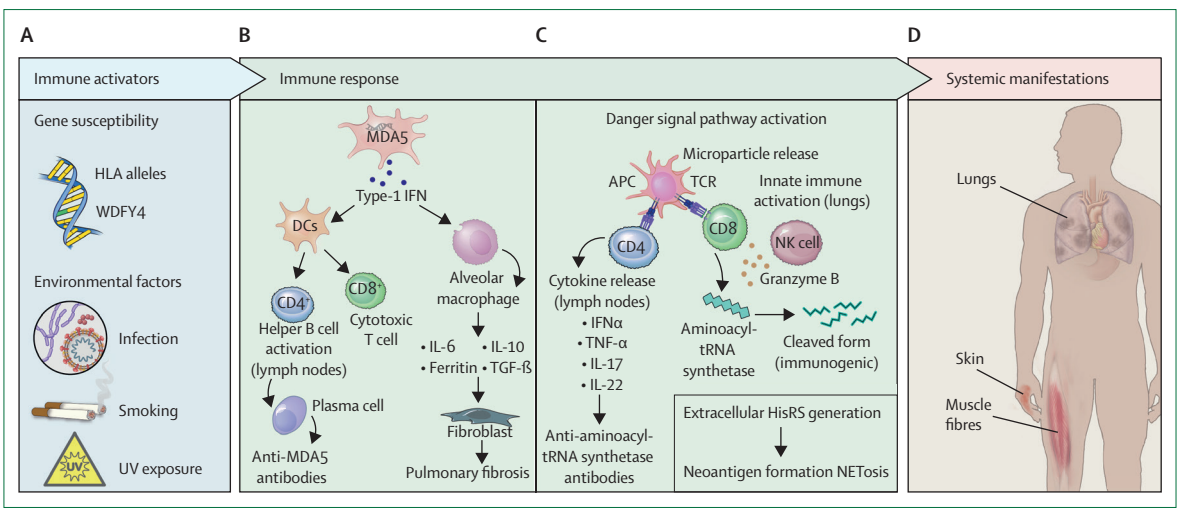

Figure 1: **Proposed pathobiology of myositis-associated ILD**
(A) Immune activators and environmental factors can trigger aberrant immune responses in a genetically susceptible individual. (B) Anti-MDA5 dermatomyositis is caused by infected cells that activate MDA5, which triggers type-1 IFN production. Virus induced cell injury and lysis, causes release of viral-MDA5 complexes that are recognised by antigen-presenting cells (macrophages) with subsequent activation of helper T cells (CD8) and B cells (CD4). As a result, there is production of anti-MDA5 autoantibodies and release of interleukins, TNF-α, and other inflammatory cytokines. (C) Antisynthetase syndrome is caused by cellular stress from epithelial injury that leads to cell death with microparticle release and danger signal pathway activation. APCs bind to TCRs on CD8+ T cells. Along with NK cell activation, proteolytic enzymes (granzyme B) are produced, which leads to HisRS generation. The release of HisRS antigen in the extracellular milieu leads to inflammatory response activation, cytokine release, and production of HisRS autoantibodies. (D) Immune activation can lead to multisystem inflammation and fibrosis in the lungs, muscle, and skin. APC=antigen-presenting cell. DC=dendritic cell. HisRS=histidyl-tRNA-synthetase. IFN=interferon. ILD=interstitial lung disease. MDA5=melanoma differentiation-associated protein 5. NETosis=neutrophil extracellular traps and cell death. NK=natural killer. TCR=T-cell receptor. TNF-α=tumour necrosis factor-α.

immune checkpoint inhibitors, d-penicillamine, interferons, and anti-TNF agents are also potential triggers.[12–14] A seasonal distribution with higher prevalence of anti-MDA5 dermatomyositis in colder months could be related to infections.[15] A higher prevalence of antisynthetase syndrome and dermatomyositis has been noted with a latitudinal gradient, suggesting an association with increased intensity of ultraviolet radiation.[16]

Antisynthetase syndrome is characterised by the development of autoantibodies directed against different tRNA-synthetase enzymes. Activation of adaptive immune cells and tolerance breakdown leads to antigen presentation, CD8+ T cell priming, and CD4-T cell–B cell crosstalk. Release of type I and type II interferons, B lymphocyte stimulator, and other cytokines lead to the production of anti-tRNA synthetase autoantibodies.[17–19] The resultant aberrant immune activation of T cells (including CD8+ and CD4+ T cells), is thought to play a central role in disease pathogenesis. Activated CD8+ T cells release granzyme B, which cleaves several aminoacyl-tRNA synthetases in the lungs.[20] Active T cells, B cells, and autoantibodies enter the systemic circulation and encounter the altered autoantigens in the lungs, resulting in lung injury. Most of the 20 known aminoacyl-tRNA synthetases could become autoantigenic; however, commercially available tests only measure antibodies against some of them.[21] The most common antibodies are anti-histidyl-tRNA-synthetase antibody or anti-Jo-1 antibody.

A subtype of dermatomyositis associated with anti-MDA5 antibody is strongly associated with rapidly progressive ILD. MDA5 is a cytosolic sensor that recognises viral double stranded RNA as a danger signal and triggers the transcription of genes encoding IFN-1 production, leading to suppression of viral replication. Viral infections might incite autoimmunity via several possible mechanisms. Viral induced MDA5 activation in genetically predisposed individuals followed by excessive cellular apoptosis could lead to a tolerance breach with lungs being the primary triggering and affected organ.[22,23] Considering the role of IFN-1 signalling pathway in anti-MDA5 dermatomyositis, JAK inhibitors have been used to treat anti-MDA5 dermatomyositis.

Clinical presentation and diagnostic testing

The classical presentation of idiopathic inflammatory myopathy includes a combination of muscle, skin, lung, and joint disease. However, patients can initially manifest symptoms affecting any of these systems in isolation. The disease can become progressive and affect other organs after initial presentation.[24] A multidisciplinary collaboration between pulmonology, rheumatology, dermatology, and neurology plays an important role in the diagnosis and management of these patients. Knowledge of the subtle signs of systemic manifestations of idiopathic inflammatory myopathy by specialists can help in early and accurate diagnosis.

Serology

Autoantibodies in idiopathic inflammatory myopathy are closely linked to clinical phenotypes. In patients with suspected IIM-ILD, antibody testing can help establish a diagnosis, predict outcomes, and play a role in determining treatments. The group of antibodies specific for idiopathic inflammatory myopathy manifestations are known as myositis-specific antibodies and those frequently found in other connective tissue diseases, which can also cause myositis, are grouped into myositis-associated antibodies. Myositis-specific antibodies include antibodies for dermatomyositis (ie, anti-MDA5, Mi-2, TIF-1γ, NXP-2, and SAE), antisynthetase syndrome (ie, anti-Jo-1, EJ, OJ, PL-7, PL-12, Ha, Zo, and Ks), immune-mediated necrotising myopathy (ie, anti-HMGCR and anti-SRP), and inclusion body myositis (ie, anti-cN1A). Myositis-associated antibodies include anti-PM/Scl, anti-U1RNP, anti-U3RNP, anti-Ku, anti-cN1A, and anti-Ro52. Details of common clinical manifestations associated with the various myositis-specific antibodies are reviewed in table 1.

Anti-nuclear antibody testing is often used to screen for connective tissue disease. Indirect immunofluorescence using human epithelial type 2 cells as a substrate, is the standard screening for anti-nuclear antibodies with quantification of the titre and anti-nuclear antibody staining pattern. Most myositis-specific antibodies show positive cytoplasmic staining and a negative nuclear staining pattern, which can lead to a negative anti-nuclear antibody test. Therefore, anti-nuclear antibody is not useful for screening for the presence of a myositis-specific antibody.

Several single and multiplex commercial assays are available for detecting most myositis-specific antibodies. These assays include ELISA, addressable laser bead immunoassays, immunoblotting techniques, and RNA or protein radio-immunoprecipitation. ELISA are the most used assay worldwide.[25] Currently, the gold standard for myositis autoantibody testing is the radio-immunoprecipitation assay, which is not commonly available. In a multinational study evaluating real world antisynthetase antibody measurement, the local or commercial measurement of anti-Jo1 antibody was reliable compared with the gold standard RNA radio-immunoprecipitation measurement. The measurement of non-Jo1 antisynthetase antibodies (anti OJ, EJ, PL-12, and PL-7) were less reliable.[26] Thus, the clinician should be aware of the limitations of the test being used and be mindful of the possibility of false-positive or false-negative results.

Based on our experience, we suggest starting with a panel that includes all eight available antisynthetase antibodies, anti-MDA5, and anti-Ro52, which are antibodies that have been associated with ILDs. Other antibodies, such as anti-HMGCR, anti-SRP, or anti-CN1A can be ordered if clinically indicated.

Myositis-specific antibody-negative IIM-ILD

Patients can present with clinical features consistent with IIM-ILD without myositis-specific antibody. Within this group, those with ILD as the first clinical manifestation represent a more challenging subgroup that requires evaluation by a multidisciplinary team of experts in IIM-ILD. Currently, standard assays only identify the eight most common antisynthetase antibodies that have been associated with IIM-ILD. However, there are other tRNA synthetases whose corresponding autoantibodies are not yet identified by standard assays. Immunoprecipitation is particularly useful in this population of myositis-specific antibody-negative IIM-ILD, as it could reveal an immunoprecipitation band representing an unidentified autoantibody. In our practice, we have observed that a considerable number of patients negative for myositis-specific antibody are positive for anti-Ro-52 autoantibody; however, studies to validate these findings are warranted. Sclafani and colleagues reported that 50 patients with ILD only positive for anti-Ro-52 autoantibody had similar outcomes compared with those with co-positivity of anti-Ro-52 and a myositis-specific antibody.[27] This finding highlights the potential role of the anti-Ro-52 autoantibody in the evaluation of patients with suspected IIM-ILD, particularly those negative for myositis-specific antibody. These patients exhibit a higher mean percent-predicted forced viral capacity (FVC) and lower total chest CT scores than patients with the anti-Jo1 autoantibody. Yoshifuji and colleagues reported that patients negative for myositis-specific antibody had similar lung function, lower ILD recurrence, and a lower response to steroids than those who tested positive for myositis-specific antibodies.[28] Larger studies and the use of novel immunoassays that can detect other antisynthetase antibodies will help to better characterise this group.

Pulmonary manifestations

Interstitial lung disease

ILD is the most common pulmonary manifestation of idiopathic inflammatory myopathy, affecting over 80% of patients with antisynthetase syndrome and anti-MDA5 dermatomyositis.[29–31] Other idiopathic inflammatory myopathy subtypes often present with muscle disease and have a much lower prevalence of and milder ILD. Lung disease preceding extrapulmonary symptoms is seen in 16–65% of patients, often by several months.[31]

Three distinct clinical presentations of IIM-ILD are frequently encountered. First, rapidly progressive ILD can be seen in an acute exacerbation of previously undiagnosed ILD or in patients with considerable worsening of ILD within 1–3 months of diagnosis. Acute hypoxic respiratory failure is commonly associated with anti-MDA5-dermatomyositis and antisynthetase syndrome, particularly with anti-Jo1, anti-PL7, and anti-PL12 antibodies. Development of spontaneous pneumomediastinum is a poor prognostic sign.[32] Second, chronic ILD manifests as insidious onset of dyspnoea and cough, which can be associated with extrapulmonary symptoms of idiopathic inflammatory myopathy. Chronic ILD is the most common presentation in patients with antisynthetase syndrome. Lastly,

sub-clinical ILD can be seen on imaging with minimal or no symptoms, particularly in patients with anti-SAE, anti-SRP, and anti-TIF1γ antibodies, which are associated with severe myositis.[33] Occasionally, patients with antisynthetase syndrome might be in this category when extrapulmonary symptoms are predominant.[31]

Chest imaging is important for establishing a diagnosis, choosing therapy, and estimating the prognosis of IIM-ILD (figure 2). A high-resolution CT scan (<1·5 mm slices) with volumetric scanning of the chest with inspiratory, and expiratory images can help characterise parenchymal disease. Prone images can assist with subtle, sub-pleural changes and distinguish from compression atelectasis or dependent oedema.[34] Non-specific interstitial pneumonia is the most common pattern in chronic ILD and is seen in more than 50% of patients with IIM-ILD and is characterised by peripheral and lower lobe predominant reticulation and ground-glass opacities with sub-pleural sparing.[31] Organising pneumonia pattern is characterised by patchy peripheral or peribronchovascular consolidation and ground-glass opacities. The presence of an organising pneumonia pattern on imaging is associated with a good response to immunosuppression and better outcomes. Concomitant presence of both non-specific interstitial pneumonia and organising pneumonia patterns are often observed in IIM-ILD.[35] A usual intestinal pneumonia pattern is characterised by sub-pleural, predominantly basilar fibrosis, honeycombing, and the absence of ground-glass opacities. Usual interstitial pneumonia has been reported in 10–30% of patients with antisynthetase syndrome, usually in advanced disease.[31] A usual interstitial pneumonia pattern is rare in anti-MDA5 dermatomyositis and is seen in less than 1% of patients.[36] Additional radiographic features have been associated with usual interstitial pneumonia due to connective tissue disease and include the concentration of fibrosis in the anterior upper lobes, exuberant honeycomb-like cysts in the fibrotic parenchyma, and lower lobe predominant fibrosis with sharp demarcation with normal lung in the craniocaudal plane.[37] The diffuse alveolar damage pattern consists of diffuse ground-glass opacities and consolidation, and is commonly seen during an acute exacerbation of chronic ILD or in rapidly progressive ILD, particularly in patients with anti-MDA5 dermatomyositis. Usual interstitial pneumonia and diffuse alveolar damage patterns are associated with poor response to treatment and worse outcomes. The imaging patterns can overlap, evolve, and progress.[38,38]

PET scans can show an increase in fluorodeoxyglucose uptake in both fibrotic and inflammatory ILD.

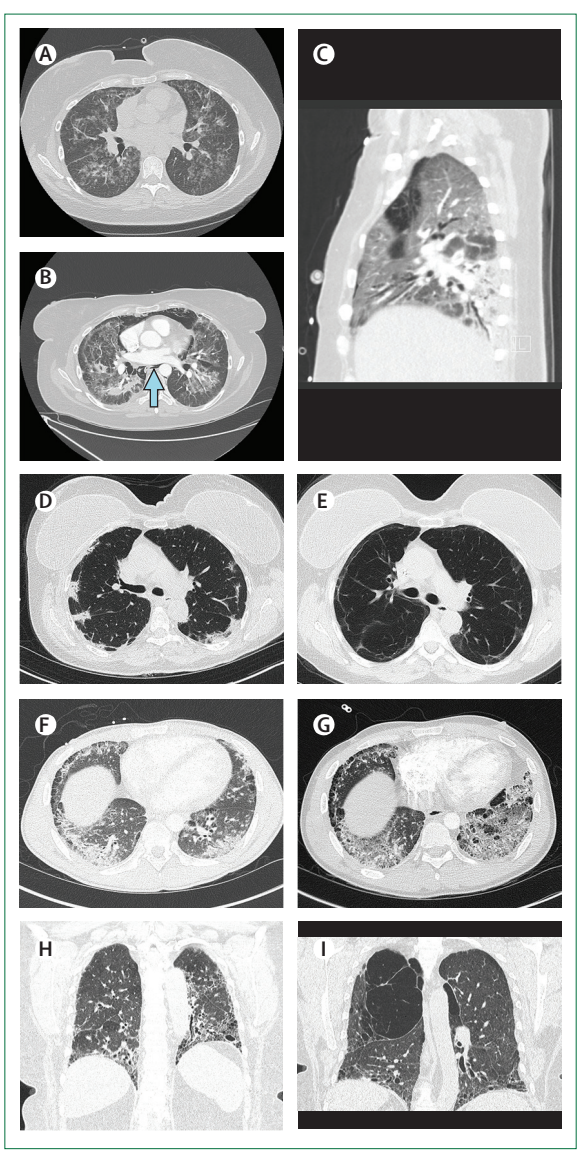

Figure 2: **Chest CT findings and evolution**
(A) Patient with rapidly progressive ILD due to anti-MDA5 dermatomyositis. A1- Axial thin-section CT with centrilobular ground-glass opacities at presentation. Axial (B) and coronal images (C) over the course of next 30 days show progressive diffuse ground-glass opacities with lower lobe predominant airspace consolidation suggestive of diffuse alveolar damage along with pneumomediastinum (blue arrow). Patient with anti-MDA5 antibody associated dermatomyositis. Axial thin-section CT (D) shows multifocal subpleural airspace opacities. Subsequent post-treatment chest CT (E) shows improvement with residual subpleural curvilinear opacities. Patient with antisynthetase syndrome (anti-PL7 antibody) axial CT (F) shows lower lobe predominant airspace opacities with ground-glass changes suggestive of organising pneumonia. Follow-up CT images on treatment (G) show the evolution to a fibrotic non-specific interstitial pneumonia imaging pattern (lower lobe predominant ground-glass opacities with traction bronchiectasis). (H) Patient with antisynthetase syndrome (anti-Jo-1 antibody). Coronal CT image shows a usual interstitial pneumonia pattern (subpleural and lower lobe predominant coarse reticulation with architectural distortion, traction bronchiectasis, traction bronchiolectasis, and honeycombing). (I) Patient with antisynthetase syndrome (anti-Jo-1 antibody). Coronal CT shows upper lobe predominant bullous emphysema with lower lobe predominant usual interstitial pneumonia pattern (subpleural reticulation, traction bronchiectasis, traction bronchiolectasis, and honeycombing). ILD=interstitial lung disease. MDA5=melanoma differentiation-associated protein 5.

In patients with IIM-ILD, an increased fluorodeoxyglucose uptake (>2·5 standardised uptake value) is more prevalent in anti-MDA5 ILD than in patients who are negative for anti-MDA5, and has been associated with worse outcomes.[40,41] PET scans are not used in routine practice, but could potentially have a role in prognostication.[42]

A restrictive pattern (ie, low total lung capacity and FVC) along with a low diffusion of carbon monoxide (DLCO) is the most common finding on pulmonary function tests (PFTs). Patients with mild disease can have an isolated mild reduction in DLCO with normal FVC. Concomitant ILD and emphysema or pulmonary hypertension might lead to a reduction in DLCO, which is out of proportion to the reduction in FVC. In patients with respiratory muscle weakness, PFTs usually reveal a decreased FVC, normal DLCO, a greater than 20% drop in FVC when laying supine, decrease in maximum voluntary ventilation, and decreased maximal inspiratory and expiratory pressures.

Lung biopsy is rarely needed to establish a diagnosis of IIM-ILD with classical clinical, radiographic, and serological presentations (appendix p 1). Occasionally, lung biopsy might be needed to rule out malignancy. Non-specific interstitial pneumonia is the most common pathological finding.[43] A usual interstitial pneumonia pattern is seen in a few patients. Both non-specific interstitial pneumonia and usual interstitial pneumonia might be associated with an acute pathology, either diffuse alveolar damage, or organising pneumonia.

Pulmonary hypertension

Pulmonary hypertension has been reported in 8–10% of patients with antisynthetase syndrome with most patients (81%) having severe disease at diagnosis. Pulmonary hypertension is most commonly associated with concomitant advanced ILD (World Symposium for Pulmonary Hypertension [WSPH] group 3 disease).[30] However, pulmonary arterial hypertension (WSPH group 1) in the absence of ILD or out of proportion to the degree of ILD has also been reported in antisynthetase syndrome and other idiopathic inflammatory myopathies.[44] Pulmonary hypertension in the absence of ILD is rare in anti-MDA5 dermatomyositis and data are limited to case reports.[45] Occasionally, pulmonary hypertension can be a consequence of myocarditis, inflammatory infiltration in the cardiac conduction system, and replacement fibrosis (WSPH group 2). Patients can present with angina, dysrhythmias, or congestive heart failure. Cardiac MRI is a sensitive technique that can detect mild inflammation in the myocardium.[46,47] Echocardiogram is used as a screening test to establish if further investigations for pulmonary hypertension are warranted, but the clinician needs to maintain a high clinical suspicion as echocardiography in patients with parenchymal lung disease can be inaccurate. The diagnosis of pulmonary hypertension requires confirmation by right heart catheterisation.

Respiratory muscle disease

Respiratory muscle (diaphragm and intercostal muscle) weakness can present with dyspnoea and orthopnoea and can progress to hypercapnic respiratory failure if severe. Isolated respiratory muscle involvement is rare. However, subclinical diaphragm weakness is common and can be seen in up to 75% of patients, often with mild symptoms and normal PFTs. Low activity levels due to myopathy could account for the absence of dyspnoea in some patients.[48] Dyspnoea in the absence of parenchymal or pulmonary vascular disease should trigger tests for muscle weakness. Diaphragmatic ultrasound is a promising, non-invasive method to assess diaphragm function by measuring diaphragm dome excursion and diaphragm thickness. This technique can accurately measure diaphragm function in other neuromuscular diseases, but clinical use in idiopathic inflammatory myopathy is yet to be established.[49]

Aspiration

Dysphagia can occur due to pharyngeal muscle weakness or oesophageal dysmotility. In the EuroMyositis registry, 26% of patients with antisynthetase syndrome and 53% of those with overlap myositis reported dysphagia,[50] which can lead to aspiration pneumonia or pneumonitis. Video-fluoroscopic swallowing study and manometry can be used to evaluate dysphagia.[51]

See Online for appendix

Respiratory infections

Respiratory infections are common in patients on immunosuppression treatment and can mimic rapidly progressive ILD or trigger an acute ILD exacerbation. The range of respiratory infections in an immunocompromised individual is wide and risks depend on the degree and type of immunosuppression.[52] High dose corticosteroids and combination immunosuppression increases the risk of opportunistic infections such as pneumocystis pneumonia. Seasonal and community acquired viral infections (eg, SARS-CoV-2 or influenza) can lead to severe and persistent disease in patients on B cell depleting therapy.[53] Infections related to environmental exposures (fungal pathogens), nosocomial infections, or reactivation of latent pathogens should be considered based on the patient's risk factors. Ruling out infection and identifying the causative pathogen is both essential and challenging. While bronchoalveolar lavage is an effective tool, the risk of respiratory decompensation in patients with a tenuous respiratory status needs to be considered. Non-invasive testing (ie, sputum, urine antigen, nasopharyngeal swab, or serological next generation sequencing) with empirical antimicrobials for common pathogens might be the only option in some patients.[54]

Constitutional symptoms

Fever is the presenting symptom in 25% of patients with antisynthetase syndrome and is seen in 40% of patients

during their disease course. Antisynthetase syndrome should be on the differential diagnosis for fever of unknown origin. Weight loss can be associated with disease activity, although other important causes, such as an underlying neoplasm, should also be considered.[55]

Musculoskeletal manifestations

Myopathy is a hallmark feature of idiopathic inflammatory myopathy (appendix p 2). The characteristic presentation is symmetric—proximal muscle weakness with hip and thigh muscles being the most frequently affected areas. Common symptoms are difficulty standing from a seated position, climbing steps, or raising arms overhead. Neck extensor muscle weakness can cause head drop and pharyngeal muscle weakness might result in dysphagia and voice change. Myalgia and muscle tenderness are common with antisynthetase syndrome. A detailed neurological examination is crucial in determining the severity and distribution of muscle weakness and to rule out myositis mimics.

In patients with antisynthetase syndrome, lung disease in the absence of or preceding myositis by months is typical.[6] The absence of myopathy is most often seen in anti-MDA5 dermatomyositis, but can also be associated with other myositis-specific antibodies. Clinically, patients with amyopathic dermatomyositis are at higher risk of developing ILD than patients with classic dermatomyositis, and clinically amyopathic dermatomyositis is considered a predictor of rapidly progressive ILD.[56–58]

The diagnostic investigations for myopathy include a variable combination of muscle enzymes, muscle MRI, electromyography, and muscle biopsy. Creatine kinase is the most sensitive and measurable muscle enzyme and can be used to monitor treatment responses and relapses. Other non-specific biomarkers of muscle injury include aldolase, lactate dehydrogenase, and aminotransferases.[59]

Bilateral thigh MRI using a myositis protocol (T1-weighted imaging, fluid-sensitive T2W with fat suppression, or short-tau inversion recovery sequence) can be used to identify early stages of myositis and target areas for a muscle biopsy. Findings include oedema of muscle fibres, alteration in muscle signal intensity, and, in later stages, presence of fatty infiltration, fibrosis, or muscle atrophy. These changes are not specific to myositis and can also be seen in injuries, muscle infarction, denervation, or rhabdomyolysis.[52,60]

Electromyography can distinguish myopathy from neuropathic causes of weakness. Myopathy is characterised by polyphasic motor unit action potentials that are of short-duration, low amplitude on voluntary activation, and with prominent muscle membrane irritability at rest. Electromyography is not diagnostic of myositis, as similar findings can occur in infectious, toxic, metabolic, or degenerative myopathies. Electromyography can guide muscle biopsy, but biopsy should not be performed on a muscle that has recently undergone electromyography testing.[61,62]

Arthritis or arthralgia is seen in 90% of patients with idiopathic inflammatory myopathy and is the presenting symptom in 30% of patients with antisynthetase syndrome.[63] Three general patterns of joint involvement are seen: (1) symmetrical, non-erosive, polyarthritis affecting the hand joints and knees (seen in around 60%); (2) isolated joint arthralgia (25%); and (3) subluxing-arthropathy affecting the distal interphalangeal joints (15%).[64] Plain radiographs typically show a non-destructive arthropathy, although erosive arthritis has been occasionally reported.[65]

Skin manifestations

The presence of classical skin findings, on history or examination, can be helpful in establishing a diagnosis; however, the appearance of skin manifestations can be affected by the patient's skin tone (figure 3). Several pathognomonic dermatomyositis skin findings have been described and can be seen in various combinations in idiopathic inflammatory myopathy. These include heliotrope rash (periorbital violaceous erythema commonly with oedema), Gottron's papules (erythematous-to-violaceous papules and plaques, overlying metacarpo-phalangeal and interphalangeal joints), Gottron's sign (erythematous macules or patches over extensor surfaces of the fingers, elbows, and knees), Shawl sign (erythema over posterior shoulders, neck, and upper back), V sign (erythema over lower anterior neck and upper chest), nailfold changes (Periungual nailfold erythema, telangiectasia, and punctate cuticular haemorrhage), Holster sign (symmetric poikiloderma of hips and lateral thighs), and mechanic's hands (non-pruritic, hyperkeratotic eruptions on the lateral surface of fingers, and common in patients with antisynthetase syndrome).

Most of these skin lesions are pruritic or burning and some can be photosensitive. Skin hypopigmentation or hyperpigmentation, atrophy, and telangiectasia resulting in poikiloderma can occur, especially on the upper chest and lateral upper arms. Patients with anti-MDA5 dermatomyositis can develop specific skin features, including skin erosions, ulcerations over joints or on digits, and tender palmar papules.

Lesional skin biopsies can be helpful in diagnosing patients with clinically amyopathic dermatomyositis and could prevent the need for muscle biopsy in patients with other idiopathic inflammatory myopathies. Characteristic histological findings include interface dermatitis with dyskeratosis, increased dermal mucin, chronic perivascular inflammation, and vascular dilatation or damage. Although these histological characteristics are essentially identical to those seen in patients with lupus erythematosus, correlation of these histological findings with serological test results and the clinical pattern and morphology of skin lesions typically allows clinicians to easily arrive at the correct diagnosis.

Nailfold capillaroscopy can aid in diagnosis and prognostication. Findings include enlarged capillaries,

Figure 3: **Dermatological manifestations of idiopathic inflammatory myopathy**
MDA5-associated dermatomyositis: (A) chest and neck ulceration, (B) livedo changes and scar around elbow, and (C) Palmar papules and ulcers. Antisynthetase syndrome: (D) Gottron's sign, (E) mechanic's hands, (F) Hiker's feet, (G) periorbital erythema, (H) arms and back pigmentation, and (I) dyspigmentation in V-neck areas. MDA5=melanoma differentiation-associated protein 5.

disorganised vascular array, capillary loss, and scleroderma-like patterns.[66] Improvement in nailfold capillaroscopy findings has been seen in response to immunosuppression and might be helpful in evaluating disease activity and response to treatment.[67–69]

Cancer-associated myositis

Adult onset idiopathic inflammatory myopathy is associated with an increased risk of malignancy, particularly within the 3 years before and 3 years after onset.[70] Furthermore, cancer is a leading cause of death in adults with idiopathic inflammatory myopathy.[71,72] Various cancers including lung, ovarian, colorectal, breast, lymphoma, and nasopharyngeal are among the most common forms. The risk and screening strategies vary considerably based on the disease phenotype and antibody profile. Patients with dermatomyositis (anti-TIF1γ and NXP-2 antibodies) older than 40 years at idiopathic inflammatory myopathy onset, dysphagia, and cutaneous necrosis are at the highest risk for having an underlying malignancy followed by patients with polymyositis, immune-mediated necrotising myopathy, or clinically amyopathic dermatomyositis who are at intermediate risk. Patients with antisynthetase antibody (anti-Jo1 or non-Jo1 antibody), myositis-associated antibodies, or anti-SRP antibody with features of Raynaud's phenomenon, inflammatory arthropathy, and ILD are at low risk. Patients can be risk-stratified based on demographics,

	Bohan and Peter (1975)[74,75]	Connors (2010)[76]	Solomon (2011)[77]	EULAR/ACR (2017)[78]
Classification criteria	Classified into definite, probable, and possible polymyositis or dermatomyositis; exclude other causes of myopathy	Positive antisynthetase antibody and any one of the following: myositis by Bohan and Peter criteria, presence of ILD, presence of arthritis, unexplained and persistent fever, Raynaud's phenomenon, or mechanic's hands	Diagnosis of antisynthetase antibody based on major and minor criteria; antisynthetase antibody positive and two major criteria or one major plus two minor criteria	Web based calculator; assigns total score and probability; sub-Classification in immune mediated myositis subtypes
Muscle manifestations	Symmetrical muscle weakness; elevation of muscle enzymes; muscle biopsy evidence of myositis; electromyography findings of myopathy	Myositis by Bohan and Peter criteria	Polymyositis or dermatomyositis per Bohan and Peter criteria (major)	Symmetrical muscle weakness; elevation of muscle enzymes; muscle biopsy findings
Skin manifestations	Characteristic dermatomyositis rash	Mechanic's hands; Raynaud's phenomenon	Mechanic's hands (minor); Raynaud's phenomenon (minor)	Heliotrope rash; Gottron's papules; Gottron's sign
Lung manifestations	Not included	ILD	ILD (major)	Not included
Serology	Not included	Antisynthetase antibody (required)	Antisynthetase antibody (required)	Anti-Jo-1 antibody
Other manifestations	··	Arthritis; unexplained fever	Arthritis (minor)	Oesophageal dysmotility
Method	Retrospective review of 153 cases	Expert opinion	Expert opinion	Analysis of data from 976 patients with immune-mediated myositis and 624 patients with non-immune-mediated myositis
Comments	Most widespread criteria for dermatomyositis or polymyositis for 40 years; does not include antibody testing; isolated lung disease	Widely used for isolated lung disease; includes all antisynthetase antibodies	Widely used for isolated lung disease; includes all antisynthetase antibodies; includes amyopathic immune-mediated myositis patients	Based on large dataset and externally validated; does not include isolated lung disease or non-Jo-1 antibody

ACR=American College of Rheumatology. EULAR=European League Against Rheumatism. ILD=interstitial lung disease.

Table 2: **Evolution of classification criteria for immune-mediated myositis**

clinical features, and antibody status. Enhanced cancer screening is recommended in patients who are at intermediate or high risk, which includes CT scans, pelvic ultrasound, mammography, cervical cancer screening, and cancer biomarkers. A whole-body PET scan should be considered in patients at high risk where other investigations have not detected a malignancy.[73]

Classification criteria for idiopathic inflammatory myopathy

Bohan and Peter provided classification criteria for dermatomyositis in 1975, which was widely used for 40 years (table 2).[74,75] They included characteristic dermatomyositis rashes and the need to exclude other causes of myopathy, but did not mention pulmonary manifestations. Patients with anti-Jo-1 antibody were recognised as having a distinct phenotype termed antisynthetase syndrome in the early 1990s.[79,80] Since then, idiopathic inflammatory myopathies have been further classified based on clinical manifestations and antibody profiles. In 2017, the first validated classification criteria of idiopathic inflammatory myopathy by the American College of Rheumatology and European Alliance of Associations for Rheumatology (EULAR) were developed and included the probability of having idiopathic inflammatory myopathy.[78] The criteria include age of onset, pattern of muscle weakness, muscle enzyme elevation, muscle biopsy findings, presence of rash, and the presence of anti-Jo-1 antibody. The criteria do not include ILD or non-Jo-1 antibodies. The criteria also do not define antisynthetase syndrome as a distinct idiopathic inflammatory myopathy subtype. There are active efforts for establishing a revised classification criteria for idiopathic inflammatory myopathy and separate classification criteria for antisynthetase syndrome that incorporate the presence of ILD. Currently, criteria suggested by Solomon and colleagues[77] and Connors and colleagues[76] based on expert opinion, are widely used to establish a diagnosis of antisynthetase syndrome. The presence of anti-synthetase antibodies with any one or two clinical features (ILD, idiopathic inflammatory myopathy, Raynaud's phenomenon, or skin changes) can be considered adequate for diagnosing antisynthetase syndrome.

Management

Immunosuppression is the mainstay of treatment for IIM-ILD targeting several pathways. As with most rare diseases, few clinical trials exist, and treatment varies based on clinical presentation and centre preference.[81] Patients with rapidly progressive ILD need early, aggressive, combination anti-inflammatory therapy. Patients with chronic ILD can be treated with a step-up escalation of therapy over several months. Patients with subclinical disease can be monitored without therapy but require close follow-up. Treatment decisions are based on expert opinion, experience, the clinical gestalt of individual treatment teams and require multidisciplinary collaboration. A summary of our recommendations on initial dosing, common adverse events, and monitoring of immunomodulators commonly used in patients with IIM-ILD are detailed in the appendix (pp 3–6).

Corticosteroids

Corticosteroids have been the first-line treatment for pulmonary and extrapulmonary manifestations of idiopathic inflammatory myopathy for decades. A meta-analysis of patients with IIM-ILD (45% antisynthetase syndrome and 40% dermatomyositis), reviewed the effect of various treatment strategies. Six studies in the analysis included 124 patients who received corticosteroid monotherapy.[82] Clinical improvement was reported in 112 (89%) of the 124 patients. However, the meta-analysis had several limitations and none of the included studies were controlled. Most studies evaluating other therapies for IIM-ILD have patients on background corticosteroids, thus limiting the data available on using a steroid-free approach.

In clinical practice, most patients are started on corticosteroids at the time of diagnosis either as a single agent or in combination with a steroid-sparing agent. In patients with rapidly progressive-ILD, high dose intravenous steroids (500–1000 mg methylprednisolone for 3 days) in combination with other immunomodulators are started. Advantages of using corticosteroids include quick onset, low cost, and physician experience. However, long-term use of corticosteroids carries considerable morbidity, including steroid myopathy. Given the morbidity associated with long-term corticosteroids, we advocate to start them in conjunction with a steroid-sparing agent early in the course of disease.

Antimetabolites

Mycophenolate mofetil (MMF), methotrexate, and azathioprine block lymphocyte activation and proliferation by inhibiting DNA synthesis via various mechanisms. In patients with IIM-ILD, antimetabolites are commonly used as first-line steroid-sparing agents due to good patient tolerance and favourable adverse effect profiles. However, data are limited to retrospective studies.

In a single-centre, retrospective study of 125 patients with connective tissue disease-associated ILD (32 [25·6%] with idiopathic inflammatory myopathy), MMF treatment led to improvement or stabilisation of disease across various underlying connective tissue diseases. Patients with usual interstitial pneumonia pathology showed stabilisation and those with non-usual interstitial pneumonia had improvement in lung function.[83] In a retrospective review of patients with IIM-ILD, both MMF and azathioprine led to improvement or stabilisation of lung function (FVC improvement of 3·6% in MMF group and 3·3% in azathioprine group) and a significant reduction in prednisone dose (6·9 mg in MMF group and 15 mg in azathioprine group) at 24 months. The rate of adverse effects was slightly higher in the azathioprine group.[84] Mira-Avendano and colleagues compared cyclophosphamide, azathioprine, and MMF as second-line agents in steroid-refractory IIM-ILD and reported that all three led to an improvement in FVC, DLCO, and dyspnoea scores at 12 months.[85] We recommend testing for thiopurine methyltransferase deficiency in patients taking azathioprine as thiopurine methyltransferase intermediate metabolisers require lower doses, and patients who are low metabolisers should not receive azathioprine.

Methotrexate has been efficacious in treating myositis and has a steroid-sparing effect; however, data for ILD are scarce.[86] Casal-Dominguez compared methotrexate with azathioprine monotherapy in 102 patients with antisynthetase syndrome.[87] Both drugs led to improvement in muscle strength, reduced corticosteroid dose requirement, and had a similar rate of adverse effects. In this cohort, two (4%) patients developed methotrexate pneumonitis. The reported incidence of pneumonitis is variable depending on the definition and cohort studied, with no reports of pneumonitis in clinical trials in patients with rheumatoid arthritis since 2001.[88] While the use of methotrexate remains a viable alternative to other antimetabolites drugs, clinicians should be aware of the clinical risk of pneumonitis.

Calcineurin inhibitors

The calcineurin inhibitors, tacrolimus and cyclosporine, restrict T cell function by inhibiting the enzyme calcineurin and impairing transcription of cytokines such as IL-2. In a randomised controlled trial, Fujisawa and colleagues compared the use of tacrolimus with cyclosporine as first add-on agents in 58 patients with IIM-ILD: 14 (24%) with clinically amyopathic dermatomyositis, ten (33%) with dermatomyositis, and six (20%) with polymyositis. Patients in both groups showed similar improvement in percentage predicted FVC (12% tacrolimus and 14% cyclosporine) and percentage predicted DLCO (23% tacrolimus and 23% cyclosporine). This trial showed efficacy of calcineurin inhibitors as first-line agents with corticosteroids, but was not designed to compare them with other treatments.[89] Therefore, calcineurin inhibitors can be used either as first-line or second-line steroid-sparing agents. The choice between tacrolimus and cyclosporine is physician dependent, with no evidence of superiority for either agent.

Rituximab

Rituximab is an anti-CD20 monoclonal antibody that causes peripheral B cell depletion. The RECITAL randomised controlled trial compared rituximab with cyclophosphamide as second-line agents in 101 patients with connective tissue disease-associated ILD (44 [43·6%] with IIM-ILD).[90] Both rituximab and cyclophosphamide increased the median FVC at 24 weeks (94 mL rituximab and 99 mL cyclophosphamide) and 48 weeks (112 mL rituximab and 138 mL cyclophosphamide). DLCO, 6-min walk distance, and quality of life also improved in both groups. The cyclophosphamide group had more total adverse effects, but both had a similar number of serious adverse events. This randomised control trial showed that most patients treated with second line rituximab or

cyclophosphamide improve, both with similar efficacy.[90] Retrospective studies have shown similar efficacy of cyclophosphamide and rituximab and a better adverse effect profile with rituximab.[91] In a systematic review of patients with anti-MDA5 ILD, 71% of patients responded to rituximab as a second-line or third-line agent.[92] Rituximab can be used as a second-line agent in refractory disease.

Cyclophosphamide

Cyclophosphamide is an alkylating agent, commonly used for cancer chemotherapy, which is used for induction in life-threatening autoimmune conditions due to its rapid and profound immune suppression. In addition to data from the RECITAL randomised controlled trial, similar findings were seen in a systematic review of five studies analysing cyclophosphamide use in patients with IIM-ILD (55% with anti-Jo-1 antibodies). In the review, 71% of patients had improvement in FVC, 69% had improvement in DLCO, and 67% had improvement in chest CT findings.[81] Cyclophosphamide can be administered up to 6 months in severe or rapidly progressive ILD, with transition to less toxic agents once the disease is in remission.

JAK inhibitors

Tofacitinib is a JAK inhibitor that preferentially inhibits JAK1 and JAK3. Tofacitinib suppresses the interferon pathway and various cytokines that are implicated in the pathogenesis of anti-MDA5-dermatomyositis. Thus, currently available data mainly focus on tofacitinib use in anti-MDA5 dermatomyositis.

In a single-centre, open-label trial with retrospective controls, Chen and colleagues studied the efficacy of tofacitinib as a first-line steroid-sparing agent in 18 patients with anti-MDA5 ILD, compared with 32 historical controls.[93] The 6-month survival was 100% in the tofacitinib group compared with 78% in controls. They reported an improvement in FVC, DLCO, and chest CT scores in the tofacitinib group. Fan and colleagues compared tofacitinib with tacrolimus in a retrospective study of patients with anti-MDA5 dermatomyositis. More than 50% of patients had rapidly progressive ILD. Lower mortality in the tofacitinib group was seen at 6 months (38·5% tofacitinib *vs* 62·9% tacrolimus) and 1 year (44·0% tofacitinib *vs* 65·7% tacrolimus).[94] Tofacitinib has also shown efficacy in patients with disease refractory to other agents.[95,96] Tofacitinib is orally dosed and can be used as a second-line or third-line agent for anti-MDA5 dermatomyositis. The use of other JAK inhibitors such as baricitinib have been reported in a case series with clinical trials ongoing.[97,98]

Intravenous immunoglobulin

Intravenous immunoglobulin (IVIg) is purified from pooled human plasma consisting of monomeric IgG. IVIg has shown efficacy in treating patients with dermatomyositis, with decreased disease activity compared with placebo.[99] In IIM-ILD, data are limited. In a retrospective study, 17 patients with antisynthetase syndrome (14 [80%] with refractory disease) were treated with IVIg for 6 months and followed up for 2 years; FVC and DLCO percentages increased, and prednisone dose decreased.[100] Most patients were on concomitant immunosuppression. The absence of a control group limits the ability to conclude IVIg efficacy. The main indication for IVIg in idiopathic inflammatory myopathy is to treat extrapulmonary disease and as second-line or third-line therapy in rapidly progressive ILD. The side-effect profile of IVIg and absence of immunosuppression makes it an attractive add-on therapy for patients with severe lung disease or in patients where active infections have not been ruled out.

Antifibrotic therapy

Nintedanib and pirfenidone have shown efficacy in treating idiopathic pulmonary fibrosis (IPF). The INBUILD randomised control trial studied the efficacy of nintedanib in 663 patients with progressive pulmonary fibrosis. In the study, 170 (25%) of the patients had connective tissue disease-associated ILD. Nintedanib slowed the rate of progression in the entire cohort. Data from patients with IIM-ILD were not reported separately.[101] In a single-centre, prospective study of patients with IIM-ILD, 39 patients on nintedanib were compared with those receiving standard-of-care therapy. Patients in the nintedanib group had a lower rapidly progressive ILD risk and better survival compared with the control group[102] In the 2022 American Thoracic Society guidelines for progressive pulmonary fibrosis, nintedanib is recommended for patients with progressive pulmonary fibrosis.[103] Pirfenidone did not meet its primary endpoint in patients with progressive pulmonary fibrosis in the RELIEF trial. Furthermore, the study had to be stopped due to poor recruitment and futility.[104]

Determining disease progression can be challenging in ILD, particularly in IIM-ILD.[105] Based on the authors' experience, we suggest a trial of adequate immunosuppression treatment with step-up as indicated after the initial diagnosis and before adding an antifibrotic.

Therapeutic plasma exchange

Therapeutic plasma exchange can decrease the levels of autoantibodies, cytokines, and immune complexes. Data for therapeutic plasma exchange in IIM-ILD is restricted to case series. In a retrospective study of 11 patients who underwent therapeutic plasma exchange for anti-MDA5 ILD, survival was ten (90%) in the therapeutic plasma exchange group compared with four (50%) of eight patients in the non-therapeutic plasma exchange group.[106] With scarce data, therapeutic plasma exchange continues to be used as a salvage therapy for rapidly progressive ILD.[107]

Lung transplantation

Lung transplantation is an option for selected patients with end-stage lung disease. Patients with progressive disease despite appropriate therapy, need for supplemental oxygen, progressive fibrotic disease, and rapidly progressive ILD should be considered for transplant evaluation.[108] In addition to standard issues of candidate selection, extrapulmonary manifestations of idiopathic inflammatory myopathy can affect candidacy and post-transplant outcomes.[109] Active myositis can affect rehabilitation potential, ventilator weaning, and the risk of aspiration. Therefore, myositis needs to be quiescent before transplant referral. Patients with considerable respiratory muscle weakness are not considered candidates for lung transplantation.

Post-transplant outcomes in IIM-ILD are similar to those for other indications in US and European cohorts.[110,111] Timely referral to an experienced transplant centre can help improve the likelihood of a successful transplant.

Pulmonary rehabilitation

Pulmonary rehabilitation is a comprehensive intervention for patients with chronic lung disease that includes exercise training and education, usually in an outpatient setting. A Cochrane review of 16 trials in patients with ILD showed that pulmonary rehabilitation helped to improve 6-min walk distance, dyspnoea, and quality of life with no significant adverse effects.[112] This treatment modality remains underutilised despite its high reward and low risk profile. Referral should be considered in all symptomatic patients with IIM-ILD.

Infection prevention and prophylaxis

Patients on immunosuppression treatment are at increased risk for infectious complications. Prophylaxis for pneumocystis pneumonia with trimethoprim–sulfamethoxazole or an alternate regimen should be started in patients on two immunosuppression medications or those on high-dose corticosteroids (>20 mg per day prednisone for 1 month). Age-specific and location-specific immunisations before initiating immunosuppression treatment and seasonal annual immunisation is strongly recommended by the authors.

Management of pulmonary hypertension

In patients with WSPH group 1 pulmonary arterial hypertension, treatment according to the latest WSPH guidelines for group 1 disease should be pursued. Immunosuppression has been reported to be beneficial in observational studies in patients with systematic lupus erythematosus and mixed connective tissue disease-associated pulmonary hypertension.[113] However, there is no supporting data in patients with idiopathic inflammatory myopathy-related pulmonary hypertension.

In patients with WSPH group 3 pulmonary hypertension due to ILD, inhaled treprostinil is recommended as it is shown to increase 6-min walk distance (mean increase 31 m), improve biomarkers of right heart failure (nt-pro BNP), and decrease the incidence of clinical deterioration (22% treprostinil *vs* 33% control).[114]

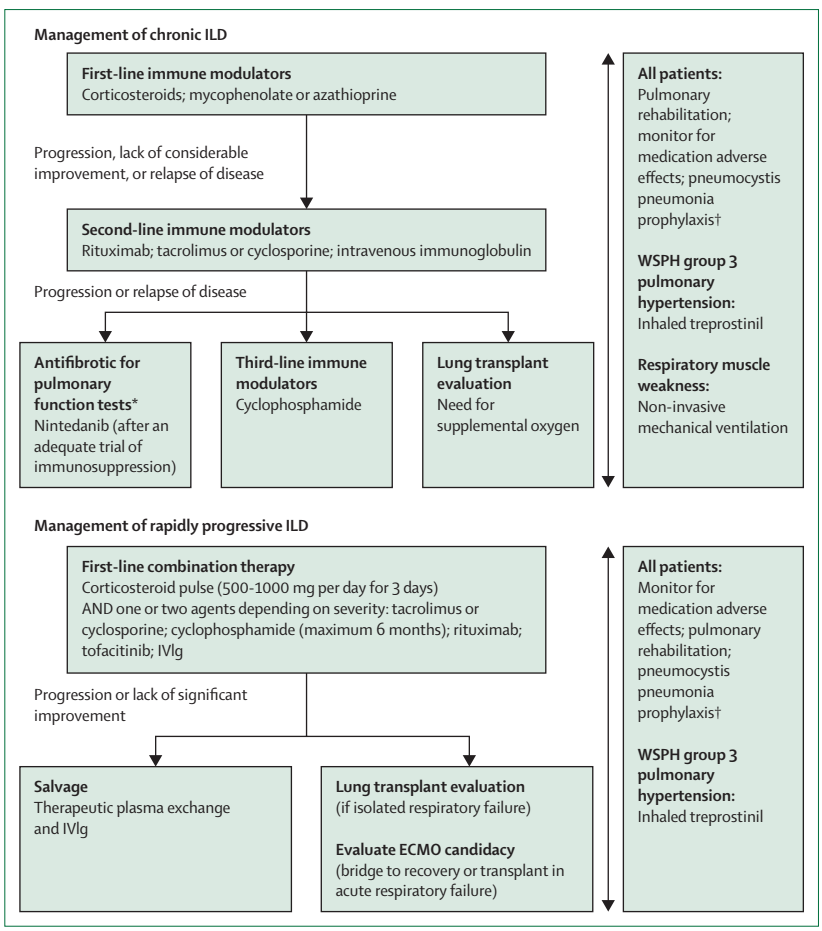

Figure 4: **Management algorithm for chronic and rapidly progressive ILD**
ILD=interstitial lung disease. ECMO=extracorporeal membrane oxygenation. IVIg=intravenous immunoglobulin. WSPH=World Symposium on Pulmonary Hypertension. *Fibrotic disease with more than 10% fibrosis on imaging and progression defined by any two or three criteria (ie, worsening respiratory symptoms, worsening pulmonary physiology, absolute decline in FVC >5% or absolute decline in DLCO >10%, or progression of disease on radiology). †Pneumocystis pneumonia prophylaxis in patients on two immunosuppressive medications or those on high-dose corticosteroids (>20 mg per day prednisone for 1 month).

Management of respiratory muscle weakness

Aggressive immune modulation with high-dose steroids, IVIg, and other agents should be initiated depending on the degree of muscle weakness. Patients need to be monitored closely for worsening disease with measurements of negative inspiratory force and vital capacity. A negative inspiratory force of less than 30 cmH_2O and FVC of less than 20 mL per kg might warrant monitoring in an intensive care unit setting. Patients might progress to respiratory failure and could require non-invasive or invasive mechanical ventilation. Management in this situation is similar to other neuromuscular diseases affecting the respiratory system.[115] Non-invasive ventilation can help improve hypercapnia, sleep quality, and quality of life in patients with chronic hypoventilation.

Monitoring

The goal of ongoing monitoring is to assess response to therapy, progression of disease, medication toxicity, infections, and comorbidities. The frequency is based on the severity, rate of disease progression, and comorbidities, and is altered to individual patient needs. In patients with chronic ILD, patients should be evaluated 1–3 months after initiating or altering therapy. Patients with rapidly progressive ILD and anti-MDA5 dermatomyositis are often admitted to hospital for rapid initiation of combination therapy. Post-hospital discharge visits are often every 2–4 weeks initially. Repeat imaging can help in assessing response to therapy by evaluating the inflammatory findings from imaging. Once the disease is deemed quiescent, patients with stable disease should be evaluated every 3–6 months.

In addition to assessing symptoms and medication toxicity, PFTs are checked (spirometry and DLCO) every 3–6 months and a chest CT scan performed as needed. At any time, worsening symptoms or hospitalisation should trigger a detailed re-evaluation, which includes investigations for infection or pulmonary hypertension. Disease can be considered progressive if there are worsening symptoms, a drop in FVC (>5%), a drop in DLCO (>10%), worsening oxygenation, or worsening parenchymal disease on imaging.[104] Progressive disease is common and is reported in 18% of patients in the first year.[116]

Treatment approach

Our management approach is based on our experience, disease acuity, severity, and comorbidities (figure 4). In patients with incidental, mild, or subclinical disease with no symptoms and normal pulmonary physiology, a wait and watch approach can be adopted. Patients should be closely monitored for the development of symptoms and PFT should be measured every 3–6 months for any signs of progression.

In patients with chronic ILD, a step-up approach should be used starting with a single agent, monitoring response, and stepping up treatment over weeks or months. First-line therapy includes moderate dose corticosteroids (prednisone 0·5–1·0 mg per kg), with tapering over 2–3 months to the lowest tolerated dose. Depending on severity, an antimetabolite is often started within weeks. We use rituximab or calcineurin inhibitors as second-line agents either alone or in combination with IVIg. Cyclophosphamide can be used as a third-line agent in refractory disease. Antifibrotic medications are added in progressive pulmonary fibrosis if there is progression on optimal anti-inflammatory therapies.

In patients with rapidly progressive ILD, aggressive therapy is started early to induce remission, followed by a step-down approach once the disease is quiescent. The favoured regimen varies based on experience and institution, but includes a combination of high-dose corticosteroids and one or two immunomodulators (eg, calcineurin inhibitors, cyclophosphamide, rituximab, IVIg, or tofacitinib). Lung transplantation should be considered early in patients with single-organ disease and respiratory failure. Several retrospective studies have reported the use of combination immunosuppression in patients with anti-MDA5 ILD.[117]

Our approach seems to be in line with guidelines from the American College of Rheumatology, British Thoracic Society, Japanese Respiratory Society, and Japan College of Rheumatology published in the past few years. There is also an ongoing European Respiratory Society and EULAR clinical practice guideline taskforce for management of connective tissue disease-associated ILD.[118–120]

Search strategy and selection criteria

We searched MEDLINE and PubMed for original articles about idiopathic inflammatory myopathy-associated interstitial lung disease published from Jan 1, 1980, to March 1, 2024. Both human and animal studies were considered. We used the terms "polymyositis" OR "dermatomyositis" OR "antisynthetase" AND "interstitial lung disease". We screened the reference lists of the articles identified for studies that fulfilled the search criteria that were not identified during the initial search. No measures were used to exclude any studies in the literature search for this Review. Only English language papers were considered.

Prognosis

The estimated 1-year survival in patients with IIM-ILD is greater than 90% and 10-year cumulative survival is around 80%.[121] When compared with patients with IPF, survival is considerably better in IIM-ILD. Patients with anti-MDA5 dermatomyositis continue to have a high short-term mortality, with 75% having a 1-year survival.[81,122,123] Acute exacerbations of ILD carry a high short-term mortality irrespective of the underlying idiopathic inflammatory myopathy. The overall age-adjusted mortality rate for IIM-ILD in the USA has been stable for the past two decades.[124] Factors associated with lower survival are anti-MDA5 and anti PL-7 antibody positivity, older age at onset, rapidly progressive ILD, poor response to therapy, elevated inflammatory markers, usual interstitial pneumonia pattern, malignancy, and concomitant pulmonary hypertension.[125–127]

Conclusions

Idiopathic inflammatory myopathies are a common cause of chronic and rapidly progressive ILD, often with isolated lung disease. Recognition of idiopathic inflammatory myopathy as a cause of ILD is essential since most patients respond to initial immunosuppression treatment.

The widespread availability of myositis-associated antibodies and testing can help improve diagnosis and phenotyping of this disease. Notably, there is an absence

of reliable biomarkers to guide therapy and monitor the clinical response. Furthermore, better diagnostic criteria for idiopathic inflammatory myopathy should recognise isolated IIM-ILD (ie, pneumomyositis) and antisynthetase syndrome.

Several treatments continue to be investigated in patients with idiopathic inflammatory myopathy, with many ongoing clinical trials. Immunomodulators targeting various pathways are being repurposed for use in IIM-ILD. Case reports have shown the benefits of daratumumab (anti-CD38 antibody), basiliximab (IL-2 receptor antagonist), tocilizumab (IL-6 antagonist), abatacept (selective co-stimulation modulator), anakinra (IL-1 receptor antagonist), and ruxolitinib (JAK inhibitor) among others.[128,129] The infusion of chimeric antigen receptor T cells that recognise CD19+ B cells can lead to their depletion and an "immune reset". This therapy has shown promise in inducing remission in patients with refractory systemic lupus erythematosus.[130] Two recent case reports showed remission in patients with refractory antisynthetase syndrome with chimeric antigen receptor T cell therapy.[131,132] Although these findings are encouraging, data are scarce, and this study is still considered investigational.

Contributors

SS and AP were responsible for conceptualisation, literature search, writing the initial draft, critical review, and revision. SC, APF, CF, RY, YL, SKD, DS, EMW, and JAH were responsible for critical review and commentary. KBH was responsible for conceptualisation, critical review, and revision of the manuscript.

Declaration of interests

APF received grants and contracts from Mallinckrodt, Novartis, Corbus, Alexion, Priovant, and Pfizer; consulting fees from Biogen, AbbVie, Novartis, Bristol-Myers Squibb, and UCB; is on the speakers' bureau for AbbVie, Mallinckrodt, Kyowa Kirin, and Novartis; is on the Board of Directors for American Society of Dermatopathology; is the Director at-large for the Rheumatologic Dermatology Society; and is on the OMERACT Shared-Decision Making Committee. YL received consulting fees from Argenx, Immunovant, and UCB; and grant support from Argenx. SKD received grants and contracts from Boehringer Ingelheim and United Therapeutics; is on steering committees for Avalyn and Bristol-Myers Squibb; is an educational speaker (non-branded) for Merck; and received royalties from UpToDate. EMW has grants from the National Institutes of Health (K08AR080808); serves as a consultant for AstraZeneca, Cabaletta Bio, Capstan Therapeutics, and Merck; and receives royalties from UpToDate. KBH received grants or contracts from aTyr Pharmaceuticals, Boehringer Ingelheim, Gossamer Bio, Merck (Acceleron), and United Therapeutics; consulting fees from aTyr Pharmaceuticals, Boehringer Ingelheim, Gossamer Bio, Merck (Acceleron), United Therapeutics, Johnson and Johnson (Actelion, Janssen), and Mistsubishi Pharmaceuticals; is on the speakers' bureau for Bayer Healthcare, Boehringer Ingelheim, Johnson and Johnson (Actelion, Janssen), Merck (Acceleron), and United Therapeutics; is on the steering committee for Boehringer Ingelheim, Gossamer Bio, Johnson and Johnson (Actelion, Janssen), Merck (Acceleron), and United Therapeutics; and is the co-founder of Zafer Therapeutics. RY is an educational speaker for Boehringer Ingelheim. All other authors declare no competing interests.

References

1 Khoo T, Lilleker JB, Thong BYH, Leclair V, Lamb JA, Chinoy H. Epidemiology of the idiopathic inflammatory myopathies. *Nat Rev Rheumatol* 2023; **19:** 695–712.

2 Selva-O'Callaghan A, Pinal-Fernandez I, Trallero-Araguás E, Milisenda JC, Grau-Junyent JM, Mammen AL. Classification and management of adult inflammatory myopathies. *Lancet Neurol* 2018; **17:** 816–28.

3 Sun KY, Fan Y, Wang YX, Zhong YJ, Wang GF. Prevalence of interstitial lung disease in polymyositis and dermatomyositis: a meta-analysis from 2000 to 2020. *Semin Arthritis Rheum* 2021; **51:** 175–91.

4 Chen Z, Hu W, Wang Y, Guo Z, Sun L, Kuwana M. Distinct profiles of myositis-specific autoantibodies in Chinese and Japanese patients with polymyositis/dermatomyositis. *Clin Rheumatol* 2015; **34:** 1627–31.

5 Betteridge Z, Tansley S, Shaddick G, et al. Frequency, mutual exclusivity and clinical associations of myositis autoantibodies in a combined European cohort of idiopathic inflammatory myopathy patients. *J Autoimmun* 2019; **101:** 48–55.

6 Pinal-Fernandez I, Casal-Dominguez M, Huapaya JA, et al. A longitudinal cohort study of the anti-synthetase syndrome: increased severity of interstitial lung disease in black patients and patients with anti-PL7 and anti-PL12 autoantibodies. *Rheumatology* 2017; **56:** 999–1007.

7 Xie H, Zhang D, Wang Y, et al. Risk factors for mortality in patients with anti-MDA5 antibody-positive dermatomyositis: a meta-analysis and systematic review. *Semin Arthritis Rheum* 2023; **62:** 152231.

8 Miller FW, Lamb JA, Schmidt J, Nagaraju K. Risk factors and disease mechanisms in myositis. *Nat Rev Rheumatol* 2018; **14:** 255–68.

9 Schiffenbauer A, Faghihi-Kashani S, O'Hanlon TP, et al. The effect of cigarette smoking on the clinical and serological phenotypes of polymyositis and dermatomyositis. *Semin Arthritis Rheum* 2018; **48:** 504–12.

10 Rider LG, Miller FW. Deciphering the clinical presentations, pathogenesis, and treatment of the idiopathic inflammatory myopathies. *JAMA* 2011; **305:** 183–90.

11 Aschman T, Schneider J, Greuel S, et al. Association between SARS-CoV-2 infection and immune-mediated myopathy in patients who have died. *JAMA Neurol* 2021; **78:** 948–60.

12 Liu SW, Velez NF, Lam C, et al. Dermatomyositis induced by anti-tumor necrosis factor in a patient with juvenile idiopathic arthritis. *JAMA Dermatol* 2013; **149:** 1204–08.

13 Jones JD, Kirsch HL, Wortmann RL, Pillinger MH. The causes of drug-induced muscle toxicity. *Curr Opin Rheumatol* 2014; **26:** 697–703.

14 Somani AK, Swick AR, Cooper KD, McCormick TS. Severe dermatomyositis triggered by interferon beta-1a therapy and associated with enhanced type I interferon signaling. *Arch Dermatol* 2008; **144:** 1341–49.

15 So H, So J, Lam TTO, et al. Seasonal effect on disease onset and presentation in anti-MDA5 positive dermatomyositis. *Front Med* 2022; **9:** 837024.

16 Hengstman GJD, van Venrooij WJ, Vencovsky J, Moutsopoulos HM, van Engelen BGM. The relative prevalence of dermatomyositis and polymyositis in Europe exhibits a latitudinal gradient. *Ann Rheum Dis* 2000; **59:** 141–42.

17 Gayed C, Uzunhan Y, Cremer I, Vieillard V, Hervier B. Immunopathogenesis of the anti-synthetase syndrome. *Crit Rev Immunol* 2018; **38:** 263–78.

18 Lo WS, Gardiner E, Xu Z, et al. Human tRNA synthetase catalytic nulls with diverse functions. *Science* 2014; **345:** 328–32.

19 Howard OM, Dong HF, Yang D, et al. Histidyl-tRNA synthetase and asparaginyl-tRNA synthetase, autoantigens in myositis, activate chemokine receptors on T lymphocytes and immature dendritic cells. *J Exp Med* 2002; **196:** 781–91.

20 Casciola-Rosen L, Andrade F, Ulanet D, Wong WB, Rosen A. Cleavage by granzyme B is strongly predictive of autoantigen status: implications for initiation of autoimmunity. *J Exp Med* 1999; **190:** 815–26.

21 Preger C, Notarnicola A, Hellström C, et al. Autoantigenic properties of the aminoacyl tRNA synthetase family in idiopathic inflammatory myopathies. *J Autoimmun* 2023; **134:** 102951.

22 Rodero MP, Crow YJ. Type I interferon-mediated monogenic autoinflammation: the type I interferonopathies, a conceptual overview. *J Exp Med* 2016; **213:** 2527–38.

23 Mehta P, Machado PM, Gupta L. Understanding and managing anti-MDA 5 dermatomyositis, including potential COVID-19 mimicry. *Rheumatol Int* 2021; **41:** 1021–36.

24 Cavagna L, Nuño L, Scirè CA, et al. Clinical spectrum time course in anti jo-1 positive antisynthetase syndrome: results from an international retrospective multicenter study. *Medicine* 2015; **94:** e1144.

25 Tansley SL, Snowball J, Pauling JD, et al. The promise, perceptions, and pitfalls of immunoassays for autoantibody testing in myositis. *Arthritis Res Ther* 2020; **22:** 117.

26 Loganathan A, Zanframundo G, Yoshida A, et al. Agreement between local and central anti-synthetase antibodies detection: results from the Classification Criteria of Anti-Synthetase Syndrome project biobank. *Clin Exp Rheumatol* 2024; **42:** 277–87.

27 Sclafani A, D'Silva KM, Little BP, et al. Presentations and outcomes of interstitial lung disease and the anti-Ro52 autoantibody. *Respir Res* 2019; **20:** 256.

28 Yoshifuji H, Fujii T, Kobayashi S, et al. Anti-aminoacyl-tRNA synthetase antibodies in clinical course prediction of interstitial lung disease complicated with idiopathic inflammatory myopathies. *Autoimmunity* 2006; **39:** 233–41.

29 Hall JC, Casciola-Rosen L, Samedy LA, et al. Anti-melanoma differentiation-associated protein 5-associated dermatomyositis: expanding the clinical spectrum. *Arthritis Care Res* 2013; **65:** 1307–15.

30 Hervier B, Meyer A, Dieval C, et al. Pulmonary hypertension in antisynthetase syndrome: prevalence, aetiology and survival. *Eur Respir J* 2013; **42:** 1271–82.

31 Marie I, Josse S, Hatron PY, et al. Interstitial lung disease in anti-Jo-1 patients with antisynthetase syndrome. *Arthritis Care Res* 2013; **65:** 800–08.

32 Huang W, Chen D, Ren F, et al. The clinical characteristics of subcutaneous and mediastinal emphysema in anti-melanoma differentiation-associated 5 positive dermatomyositis associated with interstitial lung disease. *Clin Exp Rheumatol* 2024; **42:** 262–68.

33 Albayda J, Mecoli C, Casciola-Rosen L, et al. A North American cohort of anti-SAE dermatomyositis: clinical phenotype, testing, and review of cases. *ACR Open Rheumatol* 2021; **3:** 287–94.

34 Raghu G, Remy-Jardin M, Myers JL, et al. Diagnosis of idiopathic pulmonary fibrosis. An official ATS/ERS/JRS/ALAT clinical practice guideline. *Am J Respir Crit Care Med* 2018; **198:** e44–68.

35 Wu W, Collins BF, Gardner GC, et al. Antisynthetase syndrome-related interstitial lung disease (ASyS-ILD): longitudinal imaging findings. *Eur Radiol* 2023; **33:** 4746–57.

36 Chen X, Jiang W, Jin Q, et al. Clinical, radiological and pathological features of anti-MDA5 antibody-associated interstitial lung disease. *RMD Open* 2023; **9:** e003150.

37 Chung JH, Cox CW, Montner SM, et al. CT features of the usual interstitial pneumonia pattern: differentiating connective tissue disease-associated interstitial lung disease from idiopathic pulmonary fibrosis. *AJR Am J Roentgenol* 2018; **210:** 307–13.

38 Migita K, Arai T, Jiuchi Y, et al. Predictors of mortality in patients with interstitial lung disease treated with corticosteroids: results from a cohort study. *Medicine* 2014; **93:** e175.

39 Kang EH, Lee EB, Shin KC, et al. Interstitial lung disease in patients with polymyositis, dermatomyositis and amyopathic dermatomyositis. *Rheumatology* 2005; **44:** 1282–86.

40 Liang J, Cao H, Liu Y, et al. The lungs were on fire: a pilot study of ^{18}F-FDG PET/CT in idiopathic-inflammatory-myopathy-related interstitial lung disease. *Arthritis Res Ther* 2021; **23:** 198.

41 Cao H, Liang J, Xu D, et al. Radiological characteristics of patients with anti-MDA5-antibody-positive dermatomyositis in ^{18}F-FDG PET/CT: a pilot study. *Front Med* 2021; **8:** 779272.

42 Nobashi T, Kubo T, Nakamoto Y, et al. 18F-FDG uptake in less affected lung field provides prognostic stratification in patients with interstitial lung disease. *J Nucl Med* 2016; **57:** 1899–904.

43 Marie I, Hatron PY, Dominique S, Cherin P, Mouthon L, Menard JF. Short-term and long-term outcomes of interstitial lung disease in polymyositis and dermatomyositis: a series of 107 patients. *Arthritis Rheum* 2011; **63:** 3439–47.

44 Sanges S, Yelnik CM, Sitbon O, et al. Pulmonary arterial hypertension in idiopathic inflammatory myopathies: data from the French pulmonary hypertension registry and review of the literature. *Medicine* 2016; **95:** e4911.

45 Shreyas R, Patteri A, Hayagrivas MB, et al. Fatal pulmonary arterial hypertension (PAH): a rare association of anti-MDA-5 positive juvenile dermatomyositis. *Int J Rheum Dis* 2024; **27:** e15180.

46 Khoo T, Stokes MB, Teo K, et al. Cardiac involvement in idiopathic inflammatory myopathies detected by cardiac magnetic resonance imaging. *Clin Rheumatol* 2019; **38:** 3471–76.

47 Hughes M, Lilleker JB, Herrick AL, Chinoy H. Cardiac troponin testing in idiopathic inflammatory myopathies and systemic sclerosis-spectrum disorders: biomarkers to distinguish between primary cardiac involvement and low-grade skeletal muscle disease activity. *Ann Rheum Dis* 2015; **74:** 795–98.

48 Teixeira A, Cherin P, Demoule A, et al. Diaphragmatic dysfunction in patients with idiopathic inflammatory myopathies. *Neuromuscul Disord* 2005; **15:** 32–39.

49 Fayssoil A, Behin A, Ogna A, et al. Diaphragm: pathophysiology and ultrasound imaging in neuromuscular disorders. *J Neuromuscul Dis* 2018; **5:** 1–10.

50 Lilleker JB, Vencovsky J, Wang G, et al. The EuroMyositis registry: an international collaborative tool to facilitate myositis research. *Ann Rheum Dis* 2018; **77:** 30–39.

51 Zeng R, Schmidt J. Impact and management of dysphagia in inflammatory myopathies. *Curr Rheumatol Rep* 2020; **22:** 74.

52 Ernste FC, Reed AM. Idiopathic inflammatory myopathies: current trends in pathogenesis, clinical features, and up-to-date treatment recommendations. *Mayo Clin Proc* 2013; **88:** 83–105.

53 Di Pasquale MF, Sotgiu G, Gramegna A, et al. Prevalence and etiology of community-acquired pneumonia in immunocompromised patients. *Clin Infect Dis* 2019; **68:** 1482–93.

54 Azoulay E, Russell L, Van de Louw A, et al. Diagnosis of severe respiratory infections in immunocompromised patients. *Intensive Care Med* 2020; **46:** 298–314.

55 Hamaguchi Y, Fujimoto M, Matsushita T, et al. Common and distinct clinical features in adult patients with anti-aminoacyl-tRNA synthetase antibodies: heterogeneity within the syndrome. *PLoS One* 2013; **8:** e60442.

56 Yamasaki Y, Yamada H, Ohkubo M, et al. Longterm survival and associated risk factors in patients with adult-onset idiopathic inflammatory myopathies and amyopathic dermatomyositis: experience in a single institute in Japan. *J Rheumatol* 2011; **38:** 1636–43.

57 Ye S, Chen XX, Lu XY, et al. Adult clinically amyopathic dermatomyositis with rapid progressive interstitial lung disease: a retrospective cohort study. *Clin Rheumatol* 2007; **26:** 1647–54.

58 Chen Z, Cao M, Plana MN, et al. Utility of anti-melanoma differentiation-associated gene 5 antibody measurement in identifying patients with dermatomyositis and a high risk for developing rapidly progressive interstitial lung disease: a review of the literature and a meta-analysis. *Arthritis Care Res* 2013; **65:** 1316–24.

59 Benveniste O, Goebel HH, Stenzel W. Biomarkers in inflammatory myopathies–an expanded definition. *Front Neurol* 2019; **10:** 554.

60 Zubair AS, Salam S, Dimachkie MM, Machado PM, Roy B. Imaging biomarkers in the idiopathic inflammatory myopathies. *Front Neurol* 2023; **14:** 1146015.

61 Dalakas MC. Review: an update on inflammatory and autoimmune myopathies. *Neuropathol Appl Neurobiol* 2011; **37:** 226–42.

62 Luo YB, Mastaglia FL. Dermatomyositis, polymyositis and immune-mediated necrotising myopathies. *Biochim Biophys Acta* 2015; **1852:** 622–32.

63 Hervier B, Devilliers H, Stanciu R, et al. Hierarchical cluster and survival analyses of antisynthetase syndrome: phenotype and outcome are correlated with anti-tRNA synthetase antibody specificity. *Autoimmun Rev* 2012; **12:** 210–17.

64 Meyer O, Charlanne H, Cherin P, et al. Subluxing arthropathy: an unusual manifestation of the antisynthetase syndrome. *Ann Rheum Dis* 2009; **68:** 152–53.

65 Cavagna L, Fusetti C, Montecucco C, Caporali R. Anticyclic citrullinated peptide antibodies as markers of erosive arthritis in antisynthetase syndrome. *J Rheumatol* 2010; **37:** 1967.

66 Piette Y, Reynaert V, Vanhaecke A, et al. Standardised interpretation of capillaroscopy in autoimmune idiopathic inflammatory myopathies: a structured review on behalf of the EULAR study group on microcirculation in Rheumatic Diseases. *Autoimmun Rev* 2022; **21:** 103087.

67 Selva-O'Callaghan A, Fonollosa-Pla V, Trallero-Araguás E, et al. Nailfold capillary microscopy in adults with inflammatory myopathy. *Semin Arthritis Rheum* 2010; **39:** 398–404.

68 Mugii N, Hasegawa M, Matsushita T, et al. Association between nail-fold capillary findings and disease activity in dermatomyositis. *Rheumatology* 2011; **50:** 1091–98.

69 Manfredi A, Sebastiani M, Cassone G, et al. Nailfold capillaroscopic changes in dermatomyositis and polymyositis. *Clin Rheumatol* 2015; **34:** 279–84.

70 Qiang JK, Kim WB, Baibergenova A, Alhusayen R. Risk of malignancy in dermatomyositis and polymyositis. *J Cutan Med Surg* 2017; **21:** 131–36.

71 Kang EH, Lee SJ, Ascherman DP, et al. Temporal relationship between cancer and myositis identifies two distinctive subgroups of cancers: impact on cancer risk and survival in patients with myositis. *Rheumatology* 2016; **55:** 1631–41.

72 Hočevar A, Virščeк A, Krošel M, et al. Survival of patients with Idiopathic inflammatory myopathies in Slovenia. *Front Med* 2021; **8:** 801078.

73 Oldroyd AGS, Callen JP, Chinoy H, et al. International guideline for idiopathic inflammatory myopathy-associated cancer screening: an International Myositis Assessment and Clinical Studies Group (IMACS) initiative. *Nature Rev Rheumatol* 2023; **19**: 805–17.

74 Bohan A, Peter JB. Polymyositis and dermatomyositis (first of two parts). *N Engl J Med* 1975; **292:** 344–47.

75 Bohan A, Peter JB. Polymyositis and dermatomyositis (second of two parts). *N Engl J Med* 1975; **292:** 403–07.

76 Connors GR, Christopher-Stine L, Oddis CV, Danoff SK. Interstitial lung disease associated with the idiopathic inflammatory myopathies: what progress has been made in the past 35 years? *Chest* 2010; **138:** 1464–74.

77 Solomon J, Swigris JJ, Brown KK. Myositis-related interstitial lung disease and antisynthetase syndrome. *J Bras Pneumol* 2011; **37:** 100–09.

78 Lundberg IE, Tjärnlund A. Response to: '2017 EULAR/ACR classification criteria for adult and juvenile idiopathic inflammatory myopathies and their major subgroups: little emphasis on autoantibodies, why?' by Malaviya. *Ann Rheum Dis* 2018; **77:** e78.

79 Bernstein RM, Morgan SH, Chapman J, et al. Anti-Jo-1 antibody: a marker for myositis with interstitial lung disease. *Br Med J* 1984; **289:** 151–52.

80 Tanimoto K, Nakano K, Kano S, et al. Classification criteria for polymyositis and dermatomyositis. *J Rheumatol* 1995; **22:** 668–74.

81 Ge Y, Peng Q, Zhang S, Zhou H, Lu X, Wang G. Cyclophosphamide treatment for idiopathic inflammatory myopathies and related interstitial lung disease: a systematic review. *Clin Rheumatol* 2015; **34:** 99–105.

82 Barba T, Fort R, Cottin V, et al. Treatment of idiopathic inflammatory myositis associated interstitial lung disease: a systematic review and meta-analysis. *Autoimmun Rev* 2019; **18:** 113–22.

83 Fischer A, Brown KK, Du Bois RM, et al. Mycophenolate mofetil improves lung function in connective tissue disease-associated interstitial lung disease. *J Rheumatol* 2013; **40:** 640–46.

84 Huapaya JA, Silhan L, Pinal-Fernandez I, et al. Long-term treatment with azathioprine and mycophenolate mofetil for myositis-related interstitial lung disease. *Chest* 2019; **156:** 896–906.

85 Mira-Avendano IC, Parambil JG, Yadav R, et al. A retrospective review of clinical features and treatment outcomes in steroid-resistant interstitial lung disease from polymyositis/dermatomyositis. *Respir Med* 2013; **107:** 890–96.

86 Vencovský J, Jarošová K, Macháček S, et al. Cyclosporine A versus methotrexate in the treatment of polymyositis and dermatomyositis. *Scand J Rheumatol* 2000; **29:** 95–102.

87 Casal-Dominguez M, Pinal-Fernandez I, Huapaya J, et al. Efficacy and adverse effects of methotrexate compared with azathioprine in the antisynthetase syndrome. *Clin Exp Rheumatol* 2019; **37:** 858–61.

88 Conway R, Low C, Coughlan RJ, O'Donnell MJ, Carey JJ. Methotrexate and lung disease in rheumatoid arthritis: a meta-analysis of randomized controlled trials. *Arthritis Rheumatol* 2014; **66:** 803–12.

89 Fujisawa T, Hozumi H, Kamiya Y, et al. Prednisolone and tacrolimus versus prednisolone and cyclosporin A to treat polymyositis/dermatomyositis-associated ILD: a randomized, open-label trial. *Respirology* 2021; **26:** 370–77.

90 Maher TM, Tudor VA, Saunders P, et al. Rituximab versus intravenous cyclophosphamide in patients with connective tissue disease-associated interstitial lung disease in the UK (RECITAL): a double-blind, double-dummy, randomised, controlled, phase 2b trial. *Lancet Respir Med* 2023; **11:** 45–54.

91 Langlois V, Gillibert A, Uzunhan Y, et al. Rituximab and cyclophosphamide in antisynthetase syndrome-related interstitial lung disease: an observational retrospective study. *J Rheumatol* 2020; **47:** 1678–86.

92 He C, Li W, Xie Q, Yin G. Rituximab in the treatment of interstitial lung diseases related to anti-melanoma differentiation-associated gene 5 dermatomyositis: a systematic review. *Front Immunol* 2022; **12:** 820163.

93 Chen Z, Wang X, Ye S. Tofacitinib in amyopathic dermatomyositis-associated interstitial lung disease. *N Engl J Med* 2019; **381:** 291–93.

94 Fan L, Lyu W, Liu H, et al. A retrospective analysis of outcome in melanoma differentiation-associated gene 5-related interstitial lung disease treated with tofacitinib or tacrolimus. *J Rheumatol* 2022; **49:** 1356–64.

95 Kurasawa K, Arai S, Namiki Y, et al. Tofacitinib for refractory interstitial lung diseases in anti-melanoma differentiation-associated 5 gene antibody-positive dermatomyositis. *Rheumatology* 2018; **57:** 2114–19.

96 Takanashi S, Kaneko Y, Takeuchi T. Tofacitinib in interstitial lung disease complicated with anti-MDA5 antibody-positive dermatomyositis: a literature review. *Mod Rheumatol* 2022; **32:** 231–37.

97 Harada H, Shoda H, Tsuchiya H, Misaki M, Sawada T, Fujio K. Baricitinib for anti-melanoma differentiation-associated protein 5 antibody-positive dermatomyositis-associated interstitial lung disease: a case series and literature review on Janus kinase inhibitors for the disease. *Rheumatol Int* 2024; **44:** 961–71.

98 Sugino K, Ono H, Saito M, Ando M, Tsuboi E. Successful baricitinib treatment of refractory anti-synthetase syndrome associated with interstitial lung disease. *Respirol Case Rep* 2023; **11:** e01129.

99 Aggarwal R, Charles-Schoeman C, Schessl J, et al. Trial of intravenous immune globulin in dermatomyositis. *N Engl J Med* 2022; **387:** 1264–78.

100 Huapaya JA, Hallowell R, Silhan L, et al. Long-term treatment with human immunoglobulin for antisynthetase syndrome-associated interstitial lung disease. *Respir Med* 2019; **154:** 6–11.

101 Wells AU, Flaherty KR, Brown KK, et al. Nintedanib in patients with progressive fibrosing interstitial lung diseases-subgroup analyses by interstitial lung disease diagnosis in the INBUILD trial: a randomised, double-blind, placebo-controlled, parallel-group trial. *Lancet Respir Med* 2020; **8:** 453–60.

102 Liang J, Cao H, Yang Y, et al. Efficacy and tolerability of nintedanib in idiopathic-inflammatory-myopathy-related interstitial lung disease: a pilot study. *Front Med* 2021; **8:** 626953.

103 Raghu G, Remy-Jardin M, Richeldi L, et al. Idiopathic pulmonary fibrosis (an update) and progressive pulmonary fibrosis in adults: an official ATS/ERS/JRS/ALAT clinical practice guideline. *Am J Respir Crit Care Med* 2022; **205:** e18–47.

104 Behr J, Prasse A, Kreuter M, et al. Pirfenidone in patients with progressive fibrotic interstitial lung diseases other than idiopathic pulmonary fibrosis (RELIEF): a double-blind, randomised, placebo-controlled, phase 2b trial. *Lancet Respir Med* 2021; **9:** 476–86.

105 Rajan SK, Cottin V, Dhar R, et al. Progressive pulmonary fibrosis: an expert group consensus statement. *Eur Respir J* 2023; **61:** 2103187.

106 Komai T, Iwasaki Y, Tsuchida Y, et al. Efficacy and safety of plasma exchange in interstitial lung diseases with anti-melanoma differentiation-associated 5 gene antibody positive clinically amyopathic dermatomyositis. *Scand J Rheumatol* 2023; **52:** 77–83.

107 Shirakashi M, Nakashima R, Tsuji H, et al. Efficacy of plasma exchange in anti-MDA5-positive dermatomyositis with interstitial lung disease under combined immunosuppressive treatment. *Rheumatology* 2020; **59:** 3284–92.

108 Leard LE, Holm AM, Valapour M, et al. Consensus document for the selection of lung transplant candidates: an update from the International Society for Heart and Lung Transplantation. *J Heart Lung Transplant* 2021; **40:** 1349–79.

109 Crespo MM, Lease ED, Sole A, et al. ISHLT consensus document on lung transplantation in patients with connective tissue disease: part I: epidemiology, assessment of extrapulmonary conditions, candidate evaluation, selection criteria, and pathology statements. *J Heart Lung Transplant* 2021; **40:** 1251–66.

110 Rivière A, Picard C, Berastegui C, et al. Lung transplantation for interstitial lung disease in idiopathic inflammatory myositis: a cohort study. *Am J Transplant* 2022; **22:** 2990–3001.

111 Dincheva G, Rajalingam K, Chen JW, et al. Polymyositis and dermatomyositis in lung transplantation: the national U.S. experience. *Am J Respir Crit Care Med* 2018; **197:** A7373,

112 Dowman L, Hill CJ, Holland AE. Pulmonary rehabilitation for interstitial lung disease. *Cochrane Database Syst Rev* 2014; **(10):** CD006322.

113 Jais X, Launay D, Yaici A, et al. Immunosuppressive therapy in lupus- and mixed connective tissue disease-associated pulmonary arterial hypertension: a retrospective analysis of twenty-three cases. *Arthritis Rheum* 2008; **58:** 521–31.

114 Waxman A, Restrepo-Jaramillo R, Thenappan T, et al. Inhaled treprostinil in pulmonary hypertension due to interstitial lung disease. *N Engl J Med* 2021; **384:** 325–34.

115 Khan A, Frazer-Green L, Amin R, et al. Respiratory management of patients with neuromuscular weakness: an American College of Chest Physicians clinical practice guideline and expert panel report. *Chest* 2023; **164:** 394–413.

116 Zanatta E, Cocconcelli E, Castelli G, et al. Interstitial lung disease with and without progressive fibrosing phenotype in patients with idiopathic inflammatory myopathies: data from a large multicentric cohort. *RMD Open* 2023; **9:** e003121.

117 McPherson M, Economidou S, Liampas A, Zis P, Parperis K. Management of MDA-5 antibody positive clinically amyopathic dermatomyositis associated interstitial lung disease: a systematic review. *Semin Arthritis Rheum* 2022; **53:** 151959.

118 Oldroyd AGS, Lilleker JB, Amin T, et al. British Society for Rheumatology guideline on management of paediatric, adolescent and adult patients with idiopathic inflammatory myopathy. *Rheumatology* 2022; **61:** 1760–68.

119 European Respiratory Society. Ongoing task forces. 2024. https://www.ersnet.org/science-and-research/ongoing-task-forces/ (accessed July 12, 2024).

120 Johnson SR, Bernstein EJ, Bolster MB, et al. 2023 American College of Rheumatology (ACR)/American College of Chest Physicians (CHEST) guideline for the treatment of interstitial lung disease in people with systemic autoimmune rheumatic diseases. *Arthritis Rheumatol* 2024; **76:** 1182–200.

121 Johnson C, Pinal-Fernandez I, Parikh R, et al. Assessment of mortality in autoimmune myositis with and without associated interstitial lung disease. *Lung* 2016; **194:** 733–37.

122 Ge Y, Li S, Tian X, He L, Lu X, Wang G. Anti-melanoma differentiation-associated gene 5 (MDA5) antibody-positive dermatomyositis responds to rituximab therapy. *Clin Rheumatol* 2021; **40:** 2311–17.

123 Chen H, Liu H, Lyu W, et al. An observational study of clinical recurrence in patients with interstitial lung disease related to the antisynthetase syndrome. *Clin Rheumatol* 2023; **42:** 711–20.

124 Salinas M, Solomon JJ, Fernández Pérez ER. Connective tissue disease-interstitial lung disease-associated mortality rates and years of potential life lost in the United States. *Chest* 2021; **160:** 1368–71.

125 Shi J, Li S, Yang H, et al. Clinical profiles and prognosis of patients with distinct antisynthetase autoantibodies. *J Rheumatol* 2017; **44:** 1051–57.

126 Cobo-Ibáñez T, López-Longo FJ, Joven B, et al. Long-term pulmonary outcomes and mortality in idiopathic inflammatory myopathies associated with interstitial lung disease. *Clin Rheumatol* 2019; **38:** 803–15.

127 Hannah JR, Lawrence A, Martinovic J, et al. Antibody predictors of mortality and lung function trends in myositis spectrum interstitial lung disease. *Rheumatology* 2023; published online Dec 1. https://doi.org/10.1093/rheumatology/kead638 (preprint).

128 Holzer MT, Nies JF, Oqueka T, Huber TB, Kötter I, Krusche M. Successful rescue therapy with daratumumab in rapidly progressive interstitial lung disease caused by MDA5-positive dermatomyositis. *Chest* 2023; **163:** e1–5.

129 Moghadam-Kia S, Oddis CV. Current and new targets for treating myositis. *Curr Opin Pharmacol* 2022; **65:** 102257.

130 Mackensen A, Müller F, Mougiakakos D, et al. Anti-CD19 CAR T cell therapy for refractory systemic lupus erythematosus. *Nat Med* 2022; **28:** 2124–32.

131 Müller F, Boeltz S, Knitza J, et al. CD19-targeted CAR T cells in refractory antisynthetase syndrome. *Lancet* 2023; **401:** 815–18.

132 Pecher AC, Hensen L, Klein R, et al. CD19-targeting CAR T cells for myositis and interstitial lung disease associated with antisynthetase syndrome. *JAMA* 2023; **329:** 2154–62.

Copyright © 2024 Elsevier Ltd. All rights reserved, including those for text and data mining, AI training, and similar technologies.